



PATIENT PRESENTING CLINICAL SIGNS

Loya Breckenridge History: Urinary incontinence over the last few months, polydipsia.

SPECIES Physical Examination: N/A.

Canine Urinalysis: SG 1.013, rest normal.

CBC: Normal.

BREED Serum Biochemistry: Elevated ALP activity and cholesterol.

Siberian Husky Radiographic Findings: N/A.

SEX

FS

AGE

8 years

WEIGHT

65 #

INTERPRETED BY

Remo Lobetti, BVSc,
MMedVet (Med), PhD, Dipl.
ECVIM

ULTRASONOGRAPHIC EXAMINATION OF THE ABDOMEN

Urinary System

Full urinary bladder with a normal thickness and appearance of the wall. Normal anechoic urine with no sediment or uroliths evident.

Normal trigone area, proximal urethra, and iliac blood vessels.

Normal iliac lymph nodes. Ureters not visualized.

Normal renal size (left 6.6 cm, right 6.5 cm) with increased echogenic appearance, some loss of cortico-medullary differentiation, and normal pelvis and capsule.

Reproductive System

N/A.

IMAGING PERFORMED BY

Dr Cathleen Whitcraft,
DVM

Adrenal Glands

Normal shape, echogenic appearance, position, and size. Left 0.41 /0.37 cm, right 0.45/0.41 cm.

Spleen

Normal size and echogenic appearance. Smooth homogenous parenchyma, curvilinear capsule, and normal vasculature. Focal irregular hypoechoic parenchymal non-vascularized nodule (1 x 1.1 cm) in the body of the spleen. No evidence of inflammatory, neoplastic, infarction, or infiltrative changes noted

Liver

Normal size, echogenic appearance, portal markings, and regular curvilinear capsule. No nodules or masses evident. Full gall bladder containing normal anechoic bile. Normal appearance and thickness of the gall bladder wall. Normal bile duct.

Gastrointestinal

Normal appearance of the stomach, duodenum, small intestine, ileo-cecal junction, and colon with no loss of layering, normal wall thickness and peristaltic activity, and no distension of the lumen.

INVOICE

303725

DATE

1/3/23



PATIENT *Pancreas*

Loya Breckenridge Normal size and echogenic appearance. Regular capsule. Normal echogenic appearance of the mesentery and fat surrounding the pancreas.

SPECIES *Free Abdomen*

Canine No mesenteric lymphadenomegaly.

No ascites.

BREED Round well circumscribed hypoechogenic non-vascularized nodule caudal to the stomach.

Siberian Husky

ULTRASONOGRAPHIC FINDINGS

SEX Primary Findings:

FS

AGE

8 years

- Mass/lymph node.
- Splenic nodule.
- Age-related renal changes vs renal disease.

WEIGHT INTERPRETATION OF THE FINDINGS & FURTHER RECOMMENDATIONS

65 #

Etiologies for the mass/lymph node would be reactive hyperplasia, granuloma, abscess, and neoplasia.

INTERPRETED BY

Etiologies for the splenic nodule would be hematoma, granuloma, hyperplasia, abscess, and neoplasia.

Remo Lobetti, BVSc,
MMedVet (Med), PhD, Dipl.
ECVIM

Although the appearance of the kidneys may merely be age-related changes, with the isosthenuria, early chronic kidney needs to be considered.

IMAGING PERFORMED BY

Lower urethral sphincter incompetence should also be considered.

Dr Cathleen Whitcraft,
DVM

Further assessment would be SDMA, serial monitoring of urine SG, and FNA cytology of the splenic nodule and mass/lymph node.

HOSPITAL NAME

Specific therapy would be dependent on an etiological diagnosis.

Craig Road Animal Hospital

REFERRING VET

Dr Cathleen Whitcraft,
DVM

INVOICE

303725

DATE

1/3/23



PATIENT IMAGES

Loya Breckenridge

Mass/lymph node

SPECIES

Canine

BREED

Siberian Husky

SEX

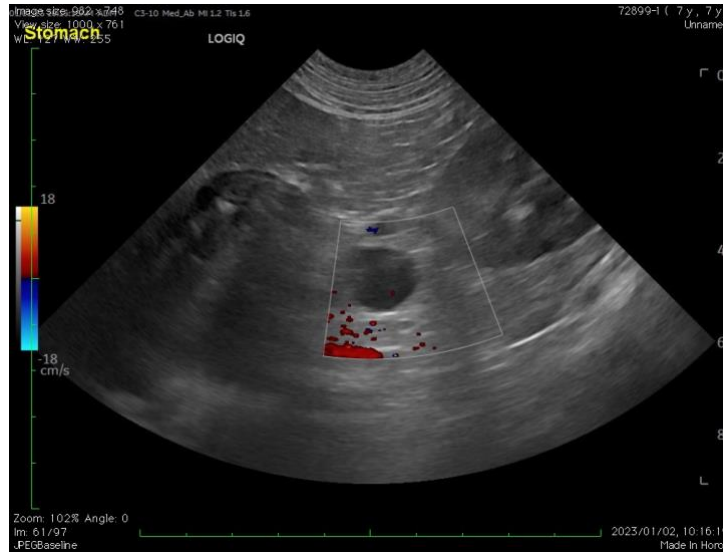
FS

AGE

8 years

WEIGHT

65 #



Spleen

INTERPRETED BY

Remo Lobetti, BVSc,
MMedVet (Med), PhD, Dipl.
ECVIM

IMAGING PERFORMED BY

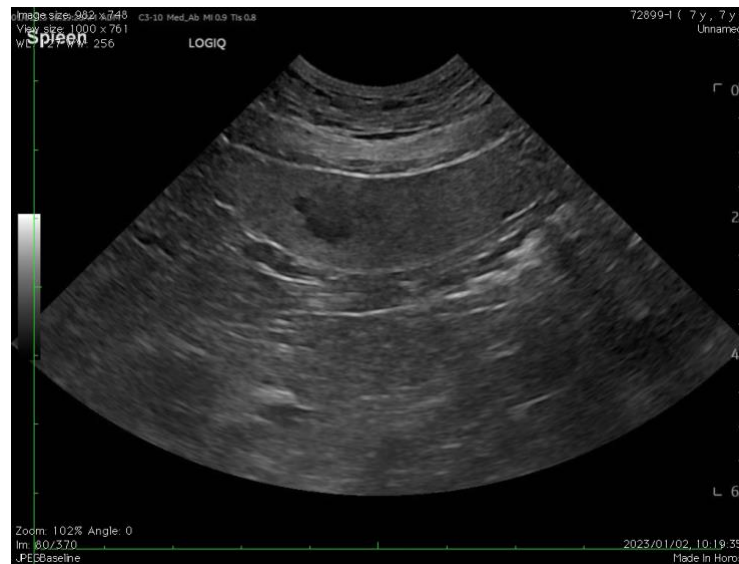Dr Cathleen Whitcraft,
DVM

HOSPITAL NAME

Craig Road Animal Hospital

REFERRING VET

Dr Cathleen Whitcraft,
DVM



INVOICE

303725

DATE

1/3/23

The information and recommendations provided are based on the images presented by the referring veterinarian. No evaluation can be communicated regarding pathology that was not visible in the image/video clips provided.

Thank you for this referral. If the clinical or image interpretation does not parallel your findings or if I can be of any further assistance, please contact me.

Remo Lobetti, BVSc, MMedVet (Med), PhD, Dipl. ECVIM (Internal Medicine)
rlobetti@mweb.co.za